23

Anomalies of the Ductus Arteriosus

JULIA GARCIA-MANCEBO AND JOHN N. KHEIR

KEY LEARNING POINTS

- The ductus arteriosus is a normal fetal vascular structure connecting the pulmonary artery and aorta. In term infants, it typically closes by 48 hours of life. Persistent patent ductus arteriosus (PDA) is more common in preterm infants and in patients born at altitude.
- Many children with an isolated PDA are asymptomatic and identified by physical exam findings, including a murmur and bounding pulses. A hemodynamically significant PDA may cause congestive heart failure, failure to thrive, and pulmonary hypertension.
- The classic murmur is described as "machinelike" with a continuous crescendo–decrescendo murmur that peaks at the second heart sound and is loudest at the second left intercostal space.
- Echocardiography is the examination of choice. The preferred views are the parasternal short-axis and the suprasternal view, localizing the descending aorta and pulmonary artery such that the PDA appears between the great vessels. Color flow mapping will help identify a PDA even if small.
- The optimal timing and method of closure remains a subject of debate. If the PDA is considered responsible for congestive heart failure, cardiogenic shock, endocarditis, or other sequelae of a hemodynamically significant shunt, timely closure is recommended. Closure can be performed with pharmacotherapy, surgery, or interventional catheterization.

Definition

The ductus arteriosus (DA) is a normal fetal vessel connecting the pulmonary and systemic circulations. This essential vascular structure allows oxygenated blood from the placenta to bypass the high-resistance pulmonary circulation and to contribute to systemic perfusion. In full-term newborns, functional closure typically occurs within 48 hours after delivery. Failure of this vessel to close beyond the third postnatal day is referred to as patent ductus arteriosus (PDA) and is considered abnormal.

Prevalence

PDA is the third most frequent congenital heart defect after ventricular and atrial septal defects. The reported incidence has increased from 0.138 in the 1970s to 1.004 per 1000 live births based on a systematic review in 2019.[1,2] Greater use of echocardiography and improved techniques for early detection may explain this trend. At Boston Children's Hospital, the number of patients in the last 20 years (2002–2021) requiring treatment for PDA has decreased, especially among the preterm infants (Table 23.1 and Fig. 23.1A and B). This is related in part to changes in clinical practice favoring expectant management.

PDA is more common in preterm infants, especially <28 weeks' gestational age (GA), with an incidence of over 50%.[3] Maternal rubella was thought to be the cause of seasonal variation, which was noted before immunization was widely introduced. Similarly, children born at elevation are at increased risk of PDA compared with those born at sea level, with the incidence increasing proportionate to birth altitude; this suggests that ductal patency may be affected by ambient oxygen fraction.[4] There are genetic contributors, with PDA more prevalent as either an isolated cardiac malformation or in combination with other defects in patients with trisomy 21, 22q11.2 deletion, Noonan syndrome, Cantú syndrome, and Cornelia de Lange syndrome among others.[5] The female-to-male ratio is reported to be as high as 2:1.

Anatomy

In normal cardiovascular development, the proximal portions of the sixth pair of embryonic aortic arches form the proximal segment of the pulmonary arteries. The distal portion of the left sixth embryonic arch persists as the DA connecting the origin of the left main pulmonary artery to the aorta, just distal to the left subclavian artery. This metamorphosis is complete by 8 weeks of fetal life.

TABLE 23.1 Boston Children's Hospital Experience 2002–2021

Age at Procedure	Thoracotomy	VATS	Catheterization	Total
<1 month	603	0	7	610
1–12 months	192	46	41	279
1–5 years	7	39	192	238
6–10 years	0	4	56	60
>10 years	0	6	46	52
Total	802	95	342	1239

The overall 30-day mortality rate following the procedure was 1.5%, all in premature babies in the thoracotomy group. None of the mortalities were deemed procedure related.
Patent Ductus Arteriosus (PDA) From 2002 to 2021, there were 1239 patients (56% female) with a primary diagnosis of PDA that required intervention. Among these were 708 (57%) premature babies up to 3 months of age. Closure management of PDA included surgery (thoracotomy, video-assisted thoracic surgery [VATS]) or by catheter-delivered devices.

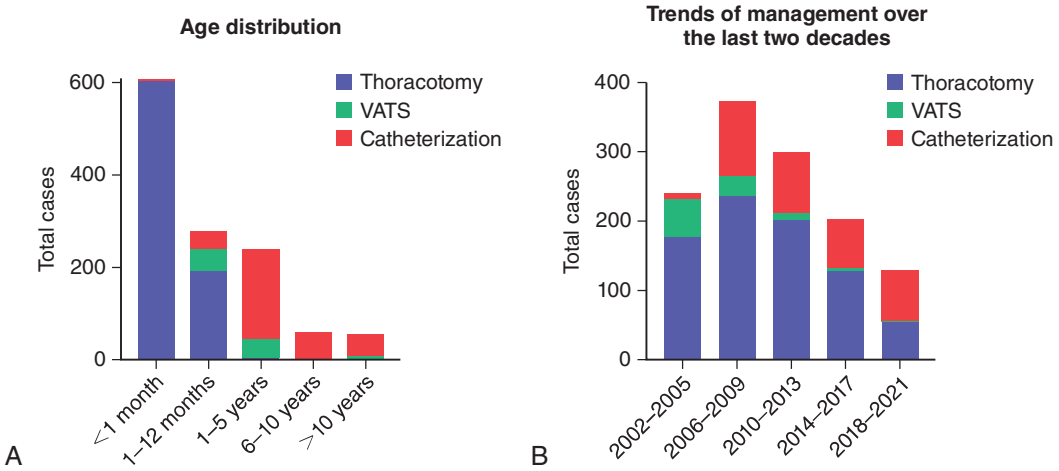

• **Fig. 23.1** (A) Patent ductus arteriosus (PDA) closure techniques by age distribution. Thoracotomy remains the primary technique in small infants, especially in premature babies, while closure with interventional procedures is the predominant approach in older children. (B) The number of patients with PDA requiring invasive treatment has decreased over time. Improvements in transcatheter methods have resulted in an increasing proportion of closures by this method. *VATS,* Video-assisted thoracic surgery.

During fetal life, the DA is as large as the ascending aorta and diverts the majority of right ventricular output to the descending aorta (Fig. 23.2); it is therefore an essential structure for normal fetal development. Fetal patency of the DA is controlled by many factors, the most important being low fetal oxygen tension and cyclooxygenase-mediated products such as prostaglandin and prostacyclin. The reciprocal relationship between the effects of oxygen and prostaglandins varies with maturity; oxygen is more effective in promoting ductal closure in the mature infant and less in the immature. Normally, the DA closes within hours of birth. Closure begins at the pulmonary end and often leaves behind a remnant on the aorta known as a ductus diverticulum. This mechanism is complex and is affected by the interaction of pulmonary and systemic arterial oxygen tensions, serum prostaglandin concentration, genetic predetermination, and other unknown factors.

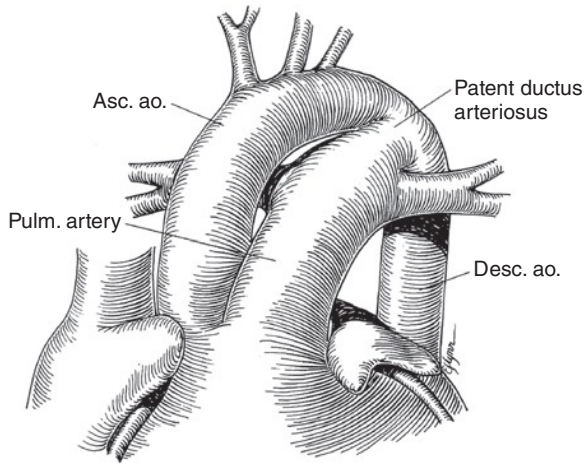

• **Fig. 23.2** Anatomic drawing of a large persistent patent ductus arteriosus. (From Fyler DC, ed. *Nadas' Pediatric Cardiology*. Philadelphia: Hanley & Belfus, 1992.)

After birth, the abrupt increase in oxygen tension inhibits ductal smooth muscle potassium channels, resulting in an influx of calcium and muscular constriction. Prostaglandin and prostacyclin levels fall following removal of placenta from the circulation. These factors cause the DA to constrict, obliterating the lumen. Functional closure usually occurs within 48 hours in term neonates. Over the following weeks, the endothelium proliferates resulting in a fibrous band that creates a permanent seal, thereafter known as the ligamentum arteriosum.[6] In premature infants, the process of ductal closure is the same but delayed, sometimes for weeks or months.

Unless managed with continuous prostaglandin or a catheter-based intervention, the DA usually becomes restrictive or closes completely in the first days of life even when the circulation depends on left-to-right (e.g., pulmonary valve atresia) or right-to-left (e.g., interrupted aortic arch) shunting for survival. Ductal closure or constriction may be induced by administration of corticosteroids or indomethacin to the mother, or by administration of indomethacin, ibuprofen, or acetaminophen to the neonate.

In some cases, a PDA persists in a variety of sizes and configurations that have implications for management. In the setting of a right aortic arch, the ductus usually remains left sided and only rarely arises in a mirror image, entering the right pulmonary artery. Bilateral ductus is rare. In pulmonary atresia, the ductus is nearly always tortuous and small; in these patients, *in utero* flow across the ductus is from the aorta to the pulmonary artery and therefore constitutes a small fraction of the normal fetal circulation. The ductus can be absent in some cases, most often in the setting of conotruncal anomalies (e.g., truncus arteriosus). The histopathology of PDA is different from that found in a normal DA, suggesting that persistent patency may be a primary anomaly and not a secondary effect.

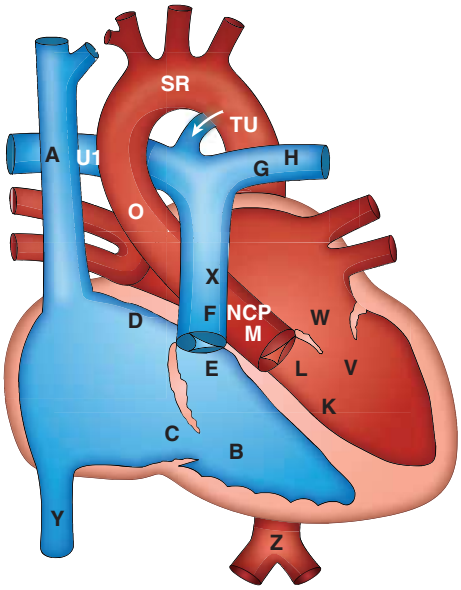

• **Fig. 23.3** Diagram of the hemodynamics in a patient with a patent ductus arteriosus and moderate pulmonary hypertension. Note the low pulmonary venous oxygen that results from a combination of an oxygen diffusion gradient in the alveolus due to extravasated lung water, due to excess pulmonary flow and hydrostatic pressure, congestive heart failure, and pulmonary infection. Note also the wide systemic arterial pressure differences owing to the diminished volume of the systemic circulation in diastole. *AO,* Aorta; *LA,* left atrium; *LV,* left ventricle; *PA,* pulmonary artery; *PV,* pulmonary vein; *RA,* right atrium; *RV,* right ventricle; *SVC,* superior vena cava.

Physiology

When an infant takes its first breaths after birth, pulmonary arteriolar resistance falls abruptly. The DA reverses flow and begins to shunt from left to right. In a matter of hours, the vessel may be functionally closed. If the DA remains widely patent, the hemodynamic impact in an otherwise normal cardiovascular system is determined by the magnitude of the shunt, which in turn depends on the size of the ductus and the relative resistance of the systemic and pulmonary circulations. The length, diameter, and tortuosity of the PDA impact shunt burden.

Generally, as pulmonary resistance falls, left-to-right (i.e., aortic to pulmonary) shunting increases. A persistent runoff from the aorta to the pulmonary artery causes excessive pulmonary blood flow, dilation of pulmonary veins and left atrium, and left ventricular volume loading (Fig. 23.3); this causes an increase in left ventricular stroke work, end-diastolic pressure, and may result in ventricular hypertrophy.[6] When the ductal shunt is extreme, left atrial dilation may "spring" open the foramen ovale, allowing left-to-right atrial shunting and right ventricular volume loading. Unrestricted aortic-to-pulmonary flow increases myocardial oxygen demand (i.e., cardiac work needs to be supranormal to provide a full cardiac output to the systemic circulation) and decreases flow to the systemic circulation, which may result in end-organ malperfusion. Increased pulmonary blood flow and pressure cause fluid extravasation into the alveoli (i.e., pulmonary edema), which requires increased lymphatic absorption to compensate. Pulmonary edema decreases lung compliance and increases work of breathing. If a PDA persists, particularly when it is unrestrictive, pathologic pulmonary vascular remodeling may become irreversible, although this is rare in the first year of life. In cases of primary or secondary pulmonary hypertension, ductal flow may be right to left (i.e., pulmonary artery to descending aorta).

Clinical Manifestations

Physical Examination

PDA in a full-term infant or child produces symptoms and signs proportionate to the size of the shunt. When restrictive, the only abnormality may be the presence of a soft murmur. When the ductus is large, symptoms of congestive heart failure or pulmonary hypertension may be present.

Peripheral arterial pulsations provide important first clues to the presence and physiology of a PDA. Normally, the arterial impulse against the examiner's finger is maximal during systole, but the artery remains palpably distended throughout diastole. The presence of a large PDA allowing continuous left-to-right shunting will result in an "emptier" systemic circulation during diastole, thereby creating the sensation of bounding pulses; the larger the left-to-right shunt, the more prominent the peripheral arterial pulsations will be.

Most children are discovered to have a murmur within days or weeks of birth. The murmur is not characteristically continuous in the early weeks of life, but it is recognized as a systolic murmur. If the PDA is large, symptoms of congestive heart failure (e.g., tachypnea, dyspnea, intercostal or subcostal retractions, hepatomegaly, or growth failure) may alert clinicians to a cardiac problem. These infants are not cyanotic unless there is pulmonary edema or reasons for abnormally elevated pulmonary vascular resistance.

Classically, in the older child, there is a crescendo systolic murmur, peaking in intensity at aortic closure and continuing into diastole as a high-frequency, decrescendo diastolic murmur (Fig. 23.4), often referred to as a "machinery murmur." Usually, though not invariably, the diastolic component of the murmur extends the entire length of diastole. Often, there are coarse sounds (clicks or "shaking dice" noises) during systole, which contribute to the machinery quality. The murmur is loudest at the second left intercostal space; maximal intensity anywhere else should cause doubt that the murmur emanates from a PDA. When shunt burden is substantial, there may be an apical diastolic rumble from excessive mitral valve flow that is difficult to differentiate from the transmitted sounds of the loud continuous murmur. In the small infant, it is uncommon to hear the diastolic component of the murmur even if the PDA is large. In older infants with a large PDA and equilibration of aortic and pulmonary pressures, there may be only a systolic murmur, usually recognizable because of its location, its crescendo quality, and occasionally a click.

The presence of a continuous murmur of crescendo–decrescendo quality, loudest at the time of the second sound, with systolic clicks, and located in the second left intercostal space should be interpreted as resulting from a PDA. Other defects that may mimic these findings include the following[7]:

1. The most common is an aortopulmonary (AP) window; however, the AP window is usually so large that an audible continuous murmur is unusual.
2. A venous hum is usually louder when the patient is sitting rather than lying down, and it may be louder to the right of the sternum. Hums have an evanescent quality, changing with respiration as well as position.
3. A fistula between a coronary artery and a cardiac chamber may produce a continuous murmur of crescendo–decrescendo quality, which is usually not loudest at the second left intercostal space. The murmur may be louder in systole or diastole, depending on the hemodynamics (see Chapter 42).
4. A ruptured sinus of Valsalva to the right chambers also produces a continuous murmur, which most often is also loudest at the second left interspace, but this is a new-onset murmur, not previously heard, and it is normally symptomatic including chest pain, dyspnea, fatigue, and syncope. These signs must prompt an echocardiogram to facilitate the diagnosis.
5. Tetralogy of Fallot with pulmonary atresia and collateral circulation produces continuous murmurs heard across the front and back of the chest. If there are sufficient collaterals, the patient may not be visibly cyanotic.

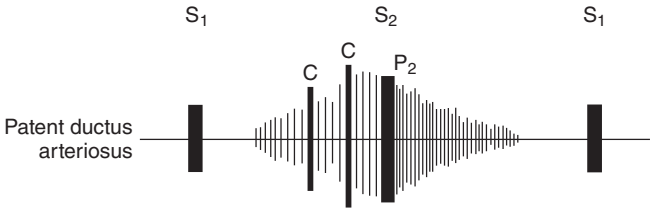

• **Fig. 23.4** Diagram of the machinery murmur of patent ductus arteriosus. Typically, the murmur is maximally loud at the time of the second heart sound *(S_2)*; clicking noises *(C)* in systole contribute to the machinery sound. (From Fyler DC, ed. *Nadas' Pediatric Cardiology*. Philadelphia: Hanley & Belfus, 1992.)

Electrocardiography

The electrocardiogram is normal when there is a small PDA. It demonstrates left ventricular hypertrophy with a larger PDA due to volume overload. Combined ventricular hypertrophy and right atrial enlargement may be present when there is a large PDA and pulmonary hypertension. When pulmonary vascular disease dominates the clinical picture, there may be only right ventricular hypertrophy.

Chest Radiograph

The aorta, left ventricle, left atrium, pulmonary vessels, and main pulmonary arteries are enlarged in proportion to the amount of left-to-right shunt and may alter the cardiac silhouette and position of the left mainstem bronchus on the plain chest radiograph. Classic findings of a large PDA include cardiomegaly, increased pulmonary vascular markings, and hyperinflation of the lungs with flattened diaphragms. Older patients who have developed pulmonary hypertension and subsequent right-to-left shunting may demonstrate pruning of the peripheral vasculature with oligemic lung fields.

Echocardiography

Echocardiography is the examination of choice to confirm and characterize a PDA. On two-dimensional echocardiography, the PDA is easily visualized, and shunting is demonstrated with color flow mapping (Fig. 23.5) even in the presence of a small shunt. The preferred views are the

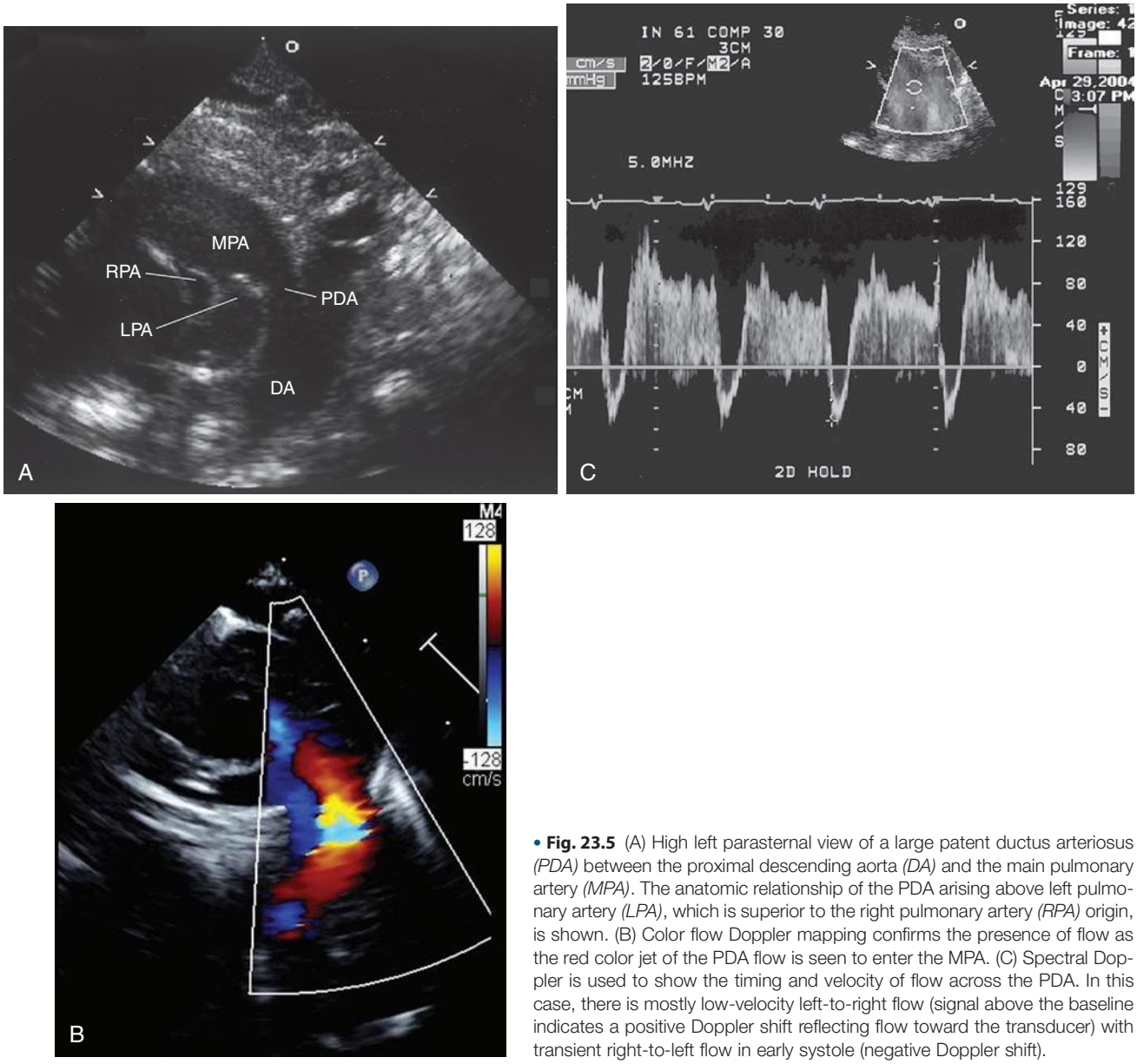

• **Fig. 23.5** (A) High left parasternal view of a large patent ductus arteriosus *(PDA)* between the proximal descending aorta *(DA)* and the main pulmonary artery *(MPA)*. The anatomic relationship of the PDA arising above left pulmonary artery *(LPA)*, which is superior to the right pulmonary artery *(RPA)* origin, is shown. (B) Color flow Doppler mapping confirms the presence of flow as the red color jet of the PDA flow is seen to enter the MPA. (C) Spectral Doppler is used to show the timing and velocity of flow across the PDA. In this case, there is mostly low-velocity left-to-right flow (signal above the baseline indicates a positive Doppler shift reflecting flow toward the transducer) with transient right-to-left flow in early systole (negative Doppler shift).

parasternal short-axis and the suprasternal view, localizing the descending aorta and pulmonary artery such that the PDA appears between these great vessels. If the ductal flow is significant, enlargement of the left atrial and ventricular chambers is evident. In many patients, incompetence of the foramen ovale allowing left-to-right shunting is evident on color flow Doppler. Estimations of pulmonary artery pressure may be made using the velocity of the tricuspid regurgitation jet, if present, and by continuous wave color Doppler. Although there is usually a pressure gradient between the aorta and pulmonary artery, absence of a gradient may reflect pulmonary hypertension. In these circumstances a PDA can be difficult to localize, but findings such as septal flattening, unexplained ventricular hypertrophy, and high-velocity pulmonary or tricuspid regurgitation should prompt further investigation.

Cardiac Catheterization

Cardiac catheterization for diagnostic purposes has not been used for many decades except to study pulmonary vascular resistance when a long-standing PDA is present. It is, however, very commonly used for interventional closure as described below.

Course

After the first successful closure of a ductus by Dr. Gross in 1938,[8] surgical management of this lesion became so widespread that a real natural history picture was no longer available. In a retrospective review by Campbell in 1968,[9] high infant mortality, spontaneous closure, endocarditis, heart failure, and pulmonary vascular obstructive disease

were described, with a mortality rate of 60% by age 60 years. At present, it is reasonable to suggest that in areas of the world with high healthcare resource utilization, diagnosis is being made at a younger age and when indicated, virtually all cases are being closed either surgically or by interventional catheterization.

In the United States, it is now extremely rare to encounter a patient with vascular obstructive disease from PDA; however, it can occur by age 2 years in an untreated large lesion. In such a patient, the characteristic murmur may be absent, the peripheral pulses may not be bounding, and the heart may not be very large. The electrocardiogram may show pure right ventricular hypertrophy. On chest radiograph, a large main pulmonary artery may be visible (Fig. 23.6). If the degree of pulmonary vascular disease is uncertain, cardiac catheterization should be considered to measure pulmonary resistance in room air, with supplemental oxygen, and with a vasodilator such as inhaled nitric oxide, both with the ductus open and with it temporarily balloon-occluded. If the resistance value is fewer than 8.0 Wood units in room air and if there is a significant decrease with the previously mentioned maneuvers, then, especially in the very young, closure by device may be undertaken at that time or by surgery shortly thereafter. Without surgery, survival for several decades with vascular obstructive disease may occur. Differential cyanosis is common in older, affected patients. There may be minimal, if any, cyanosis of the lips and fingers because fully saturated blood comes to these sites from the left ventricle, whereas clubbing and obvious cyanosis of the toes result from the right-to-left shunting through the PDA into the descending aorta. This shunt of desaturated blood also results in increased renal erythropoietin and hemoglobin production, with surprisingly high levels of the latter in the face of minimal upper body desaturation.

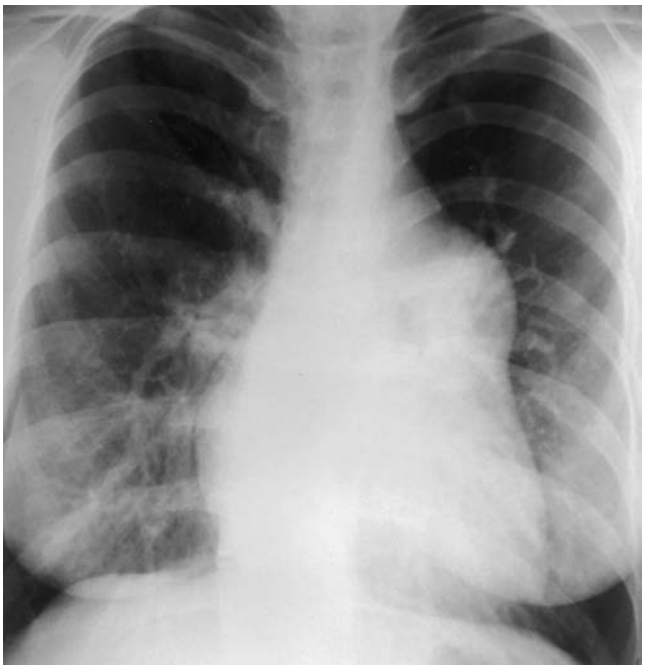

• **Fig. 23.6** Chest radiograph in a young woman with a large patent ductus arteriosus and advanced pulmonary vascular disease. This patient died within a year after this picture was taken. Note the very large main pulmonary artery and the near normal size of the heart. (From Fyler DC, ed. *Nadas' Pediatric Cardiology*. Philadelphia: Hanley & Belfus, 1992.)

An untreated PDA is a favored site for infective endocarditis. The chance of developing endocarditis has been estimated at 0.45% per year.[9] Closure of the ductus eliminates this possibility.

In the past, late spontaneous closure of a small patent ductus, largely based on auscultation, was noted on a few occasions; since the advent of echocardiography and color flow, this is now rarely encountered.

Management

The goal of management of uncomplicated PDA is to interrupt the left-to-right shunt. Indications for intervention include elimination of congestive heart failure and promotion of growth in the small infant, prevention of infective endocarditis, and prevention of pulmonary vascular disease. For practical purposes, every isolated PDA should be closed.

Closure can be accomplished with minimal risk using a variety of techniques. Pharmacotherapy with indomethacin, ibuprofen, or acetaminophen has been associated with renal and gastrointestinal complications in some cohorts but is generally considered a low-risk initial strategy in neonates.[10]

Interventional catheterization techniques for PDA closure are increasingly common (Table 23.1 and Fig. 23.1B).[11] In the current era, this approach may be done on an outpatient basis and avoid the risks of the traditional surgical approach. It is technically easier to do when the PDA is restrictive, long, and has an ampulla at the aortic end. The technique continues to evolve. Currently, coils are frequently used in small lesions, while occlusion devices are considered for moderate and large PDA. A catheter or sheath is advanced across the ductus from either of the great vessels and the closure device is positioned within the lumen of the PDA (Fig. 23.7). Complete closure rates generally exceed 95%.[12] Catheter-based closure in infants (<1 year of age) is an active area of research with regards to feasibility and safety.[13]

Age and size do not preclude surgical management. The surgical approach is most commonly via thoracotomy with exposure of the PDA, ligation, and division and has excellent results at all ages and sizes. Video-assisted thoracoscopic surgery and robotic-assisted surgery may be used for this lesion. Successful closure of PDA via surgical techniques is reported to be 95–100%, with low mortality (<3%). Compared with interventional catheterization, however, surgical ligation has been associated with higher resource use, longer duration of postoperative admission, and higher in-hospital mortality in some circumstances.[14] Ductal ligation has been followed by later appearance of a left-to-right shunt because of either incomplete ligation or recanalization. Dividing the ductus and oversewing the stumps prevents recanalization; however, the difficulties and dangers of

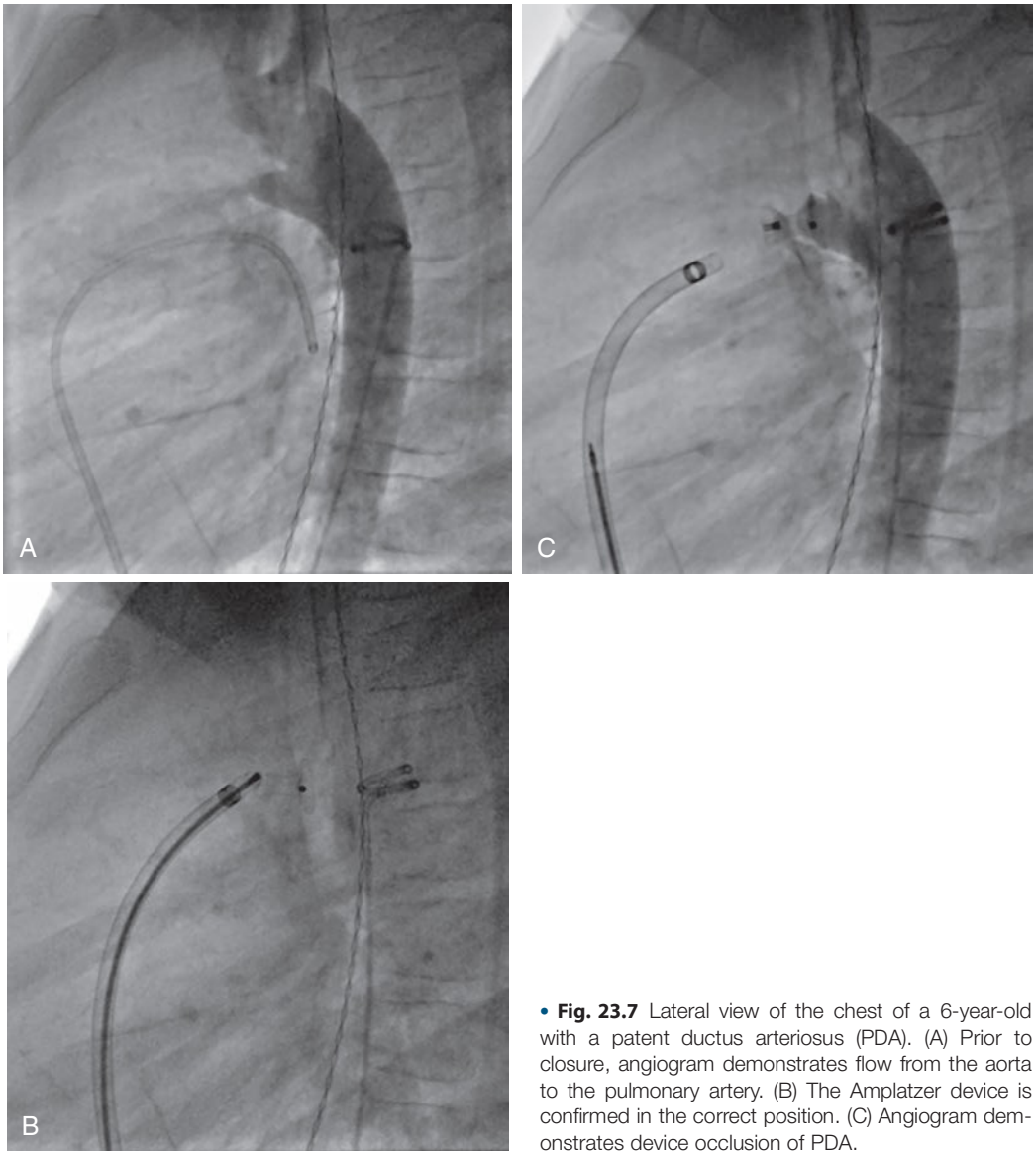

• **Fig. 23.7** Lateral view of the chest of a 6-year-old with a patent ductus arteriosus (PDA). (A) Prior to closure, angiogram demonstrates flow from the aorta to the pulmonary artery. (B) The Amplatzer device is confirmed in the correct position. (C) Angiogram demonstrates device occlusion of PDA.

division, although small, are nonetheless sufficient that some surgeons favor ligation.

Close monitoring and follow-up are necessary for infants with PDA. Effective closure should be confirmed, screening for potential complications of interventions should be performed, and early and midterm follow-up is encouraged. Long-term evaluation has generally been considered unnecessary for corrected PDA, although as we learn more about the lifelong implications of congenital heart disease, even in those patients repaired as infants, that perspective may change.

Variations

Ductus Arteriosus in Premature Infants

Prevalence

Functional closure of the DA occurs in 90% of full-term newborns within a couple of days of life. In premature infants, ductal closure may be delayed, but will occur in almost all neonates ≳30 weeks' GA by day 4. In younger GA infants, the incidence of PDA beyond this time increases, but two-third of preterm infants weighing 1000–1500 g will exhibit spontaneous ductal closure by day 7 and almost 90% by the end of their first year. Among infants ≤27 weeks' GA (or weighing <1000 g), spontaneous closure is less frequent, and one out of four infants discharged with a PDA will require intervention.[15]

Anatomy

PDA in the preterm infant is considered a result of vascular immaturity, as the preterm ductus is structurally different from mature vessels. The intima in the mature ductus is thickened and irregular with mucoid material sometimes referred to as intimal cushions, which are absent in the preterm ductus. Additionally, the preterm PDA has fewer layers of smooth muscle, which may deter postnatal ductal constriction.

Physiology

The level of pulmonary vascular resistance is less in preterm infants than in full-term babies. This favors left-to-right shunting in the presence of PDA. The presence of hypoxemia due to lung disease promotes continued patency of the ductus. Increased pulmonary blood flow and pressure may cause pulmonary hemorrhage. In addition, ductal steal from the systemic circulation may reduce intestinal flow predisposing infants to necrotizing enterocolitis, or cause fluctuations in cerebral blood flow contributing to intraventricular hemorrhage and other neurologic morbidities.[3] Pulmonary venous oxygen desaturation and pulmonary hypertension were consistent features in premature infants with PDA undergoing cardiac catheterization in earlier eras.

Clinical Manifestations

The murmur in premature infants is usually atypical, rarely being more than a systolic murmur, and not necessarily crescendo. Indeed, any systolic murmur in a very small premature baby should be considered indicative of a PDA until proven otherwise. Rarely, a premature infant may have a known PDA with no audible murmur. Prominence of the peripheral pulses is a good indication that the PDA may be pathophysiologic.

Characterizing hemodynamic significance of a PDA in preterm infants can be challenging, but growing consensuses agrees that a comprehensive appraisal of the cardiovascular status incorporating echocardiography can provide hemodynamic information that either complements what is clinically suspected or delivers novel physiologic insight.[16,17] Several clinical and echocardiographic elements are considered to define hemodynamic significance: (1) PDA shunt volume assessment and its impact on the systemic and pulmonary circulations; (2) myocardial systolic and diastolic function; and (3) antenatal and perinatal characteristics that may mitigate or exacerbate the consequences of a shunt.[18] Evidence suggests that this approach provides an accurate predictive definition of hemodynamic significance with a link to morbidity.[19]

Management

Non-interventional conservative management of PDA may be beneficial in selected patients.[20] Medical management includes ventilatory support and fluid restriction. Oxygen therapy may facilitate PDA closure in some cases, but it should be balanced with the increased risk of morbidities such as retinopathy of prematurity. Pharmacotherapy with indomethacin, ibuprofen, and/or acetaminophen has been shown to be effective.[3,21-23]

While there is no one set of clinical or echocardiographic features that necessitate PDA closure, a thorough appraisal of all factors may result in an improved risk prediction. This in turn facilitates a more accurate and targeted selection of infants more likely to benefit from invasive treatment. Definitive PDA closure should be considered in preterm babies with hemodynamically significant shunts determined by a combination of echocardiographic and clinical variables (e.g., tachycardia, tachypnea, respiratory support, abdominal symptoms, or other signs of organ dysfunction), when adjusted by individual risk factors for adverse events, including GA and other comorbilities.[24] Surgical ligation is associated with a higher risk profile and therefore risks and benefits should be weighed if medical treatment is not successful or is contraindicated.[25] Catheterization-based closure is increasingly common in preterm infants, with newer devices approved for patients as small as 700 g.[26]

Course

It is not clear whether a PDA increases the overall mortality rate in neonates as studies offer conflicting data. The mortality associated with surgical closure has improved significantly over time and the morbidities associated with interventional procedures are diminishing rapidly.

Aneurysm of the Ductus Arteriosus

Aneurysm of the DA can occur after infective endarteritis, surgical closure, or transcatheter occlusion. A variation of the normal ductus diverticulum, the remnant of the ductus at the point of attachment of the aorta, can become aneurysmal.[27] In up to 20% of these cases, an underlying genetic condition is present (e.g., Ehlers-Danlos syndrome, Marfan syndrome, trisomy 21 or trisomy 13). Most of them have a benign course and remain asymptomatic, but there is a potential risk of local compression of adjacent structures or clot formation, with subsequent increased risk of emboli or infection. Surgical resection may be indicated.

Maternal Rubella

Rubella infection in the first trimester of pregnancy is a leading cause of vaccine-preventable birth defects worldwide. Congenital rubella syndrome is typically associated with cataracts, hearing impairment, developmental delay, and congenital heart disease, oftentimes PDA or peripheral pulmonary artery stenosis.

Acknowledgment

We thank Philip T. Levy, MD, for his expert contributions to the section on Clinical Manifestations and Management of the preterm infant with PDA.

References

1. Fyler DC, Buckley LP, Hellenbrand WE, et al. Report of the New England regional infant cardiac program. *Pediatrics*. 1980;65:398.
2. Liu Y, Chen S, Zühlke L, Black GC, et al. Global birth prevalence of congenital heart defects 1970-2017: updated systematic review and meta-analysis of 260 studies. *Int J Epidemiol*. 2019;48:455-463.
3. Hamrick SEG, Sallmon H, Rose AT, et al. Patent ductus arteriosus of the preterm infant. *Pediatrics*. 2020;146:e20201209.

4. Zheng JY, Tian HT, Zhu ZM, et al. Prevalence of symptomatic congenital heart disease in Tibetan school children. *Am J Cardiol*. 2013;112:1468-1470.
5. Pierpont ME, Brueckner M, Chung WK, et al. American Heart Association Council on Cardiovascular Disease in the Young; Council on Cardiovascular and Stroke Nursing; and Council on Genomic and Precision Medicine. Genetic Basis for Congenital Heart Disease: Revisited: A Scientific Statement From the American Heart Association. *Circulation*. 2018;138:e653-e711.
6. Crockett SL, Berger CD, Shelton EL, Reese J. Molecular and mechanical factors contributing to ductus arteriosus patency and closure. *Congenit Heart Dis*. 2019;14:15-20.
7. Ginghină C, Năstase OA, Ghiorghiu I, Egher L. Continuous murmur: the auscultatory expression of a variety of pathological conditions. *J Med Life*. 2012;5:39-46.
8. Gross RE, Hubbard JP. Surgical ligation of a patent ductus arteriosus. Report of the first successful case. *JAMA*. 1939;112:729-731.
9. Campbell M. Natural history of persistent ductus arteriosus. *Br Heart J*. 1968;30:4.
10. Ferguson JM. Pharmacotherapy for patent ductus arteriosus closure. *Congenit Heart Dis*. 2019;14:52-56.
11. O'Byrne ML, Millenson ME, Grady CB, et al. Trends in transcatheter and operative closure of patent ductus arteriosus in neonatal intensive care units: analysis of data from the Pediatric Health Information Systems Database. *Am Heart J*. 2019;217:121-130.
12. Baruteau AE, Hascoët S, Baruteau J, et al. Transcatheter closure of patent ductus arteriosus: past, present and future. *Arch Cardiovasc Dis*. 2014;107:122-132.
13. Backes CH, Rivera BK, Bridge JA, et al. Percutaneous patent ductus arteriosus (PDA) closure during infancy: a meta-analysis. *Pediatrics*. 2017;139:e20162927.
14. Kuntz MT, Staffa SJ, Graham D, et al. Trend and outcomes for surgical versus transcatheter patent ductus arteriosus closure in neonates and infants at US Children's Hospitals. *J Am Heart Assoc*. 2022;11:e022776.
15. Clyman RI, Couto J, Murphy GM. Patent ductus arteriosus: are current neonatal treatment options better or worse than no treatment at all? *Semin Perinatol*. 2012;36:123-129.
16. Afif EK, James AT, Corcoran JD, et al. A patent ductus arteriosus severity score predicts chronic lung disease or death before discharge. *J Pediatr*. 2015;167:1354-1361.e2.
17. Van Laere D, Van Overmeire B, Gupta S, et al. Application of NPE in the assessment of a patent ductus arteriosus. *Pediatr Res*. 2018;84:46-56.
18. Kluckow M, Lemmers P. Hemodynamic assessment of the patent ductus arteriosus: beyond ultrasound. *Semin Fetal Neonatal Med*. 2018;23:239-244.
19. Fink D, El-Khuffash A, McNamara PJ, Nitzan I, Hammerman C. Tale of Two patent ductus arteriosus severity scores: similarities and differences. *Am J Perinatol*. 2018;35:55-58.
20. Clyman RI, Liebowitz M, Kaempf J, et al. PDA-TOLERATE trial: an exploratory randomized controlled trial of treatment of moderate-to-large patent ductus arteriosus at 1 week of age. *J Pediatr*. 2019;205:41-48.e6.
21. Kluckow M, Jeffery M, Gill A, Evans N. A randomized placebo-controlled trial of early treatment of the patent ductus arteriosus. *Arch Dis Child Fetal Neonatal Ed*. 2014;99:F99-F104.
22. Mitra S, Florez ID, Tamayo ME, et al. Association of placebo, indomethacin, ibuprofen, and acetaminophen with closure of hemodynamically significant patent ductus arteriosus in preterm infants: a systematic review and metaanalysis. *JAMA*. 2018;319:1221-1238.
23. Bardanzellu F, Neroni P, Dessì A, Fanos V. Paracetamol in patent ductus arteriosus treatment: efficacious and safe? *BioMed Res Int*. 2017;2017:1438038.
24. Sung SI, Chang YS, Kim J, Choi JH, Ahn SY, Park WS. Natural evolution of ductus arteriosus with noninterventional conservative management in extremely preterm infants born at 23-28 weeks of gestation. *PLoS One*. 2019;14(2):e0212256.
25. Su BH, Lin HY, Chiu HY, Tsai ML, Chen YT, Lu IC. Therapeutic strategy of patent ductus arteriosus in extremely preterm infants. *Pediatr Neonatol*. 2020;61:133-141.
26. Sathanandam SK, Gutfinger D, O'Brien L, et al. Amplatzer Piccolo Occluder clinical trial for percutaneous closure of the patent ductus arteriosus in patients ≥700 grams. *Catheter Cardiovasc Interv*. 2020;96:1266-1276.
27. Jan SL, Hwang B, Fu YC, Chai JW, Chi CS. Isolated neonatal ductus arteriosus aneurysm. *J Am Coll Cardiol*. 2002;39:342-348.